



# A Case Report on Late-onset Friedrich's Ataxia and Response on Parkinsonism Treatment

Uma Datta Gupta<sup>1\*</sup> and Tutul Chowdhury<sup>2</sup>

<sup>1</sup>Chittagong Medical College, Bangladesh.

<sup>2</sup>One Brooklyn Health System, United States of America.

## Authors' contributions

This work was carried out in collaboration between both authors. All authors read and approved the final manuscript.

## Article Information

DOI: 10.9734/IJMPCR/2021/v14i330133

### Editor(s):

(1) Dr. Sivapatham Sundaresan, SRM Medical College Hospital & Research Centre, SRM Institute of Science and Technology, India.

### Reviewers:

(1) V. Ramakrishnan, Chettinad Academy of Research and Education, India.

(2) Antonio Luque de La Rosa, Universidad de Almería, Spain.

Complete Peer review History: <https://www.sdiarticle4.com/review-history/72138>

Case Study

Received 06 July 2021  
Accepted 12 August 2021  
Published 14 August 2021

## ABSTRACT

Friedrich's ataxia is a progressive neurodegenerative disease that affects the posterior cord of the spinal tract. We present a case of an 83-year-old male with resting tremor and rigidity that had gradually worsened over the past few years. The patient has been diagnosed with Friedrich's ataxia. Unlike typical Friedrich ataxia, this patient does not have a shortened life expectancy. There is a small percentage of atypical patients demonstrate late-onset of disease, isolated spastic paraparesis without ataxia, and retained or exacerbated deep tendon reflex. Although there is no association between Parkinson's disease and Friedrich's ataxia; in our case, treatment of tremor and rigidity improves the patient's quality of life.

**Keywords:** Friedrich's ataxia; Parkinson's disease; Frataxin, Levodopa-Carbidopa; cognitive function.

## 1. INTRODUCTION

Friedrich's ataxia is the most common cause of inherited ataxia. It affects 1-2 persons per

100,000 with carrier frequency 1 in 120 [1]. However, less than 5% of Friedrich's ataxia patients have compound heterogeneity (In the context of Friedrich's ataxia, compound

\*Corresponding author: E-mail: [umadg0015@gmail.com](mailto:umadg0015@gmail.com);

heterogeneity refers to a lower number of the repeat on one allele (66-1700) and point mutation in another allele) [2]. Loss of function mutations by a trinucleotide (GAA) repeating in the Frataxin (FXN) gene (located on chromosome 9q13) is the most common cause of Friedrich's ataxia. The result of this mutation is the silencing of this gene and decreased production of "Frataxin", which causes an accumulation of iron in mitochondria. The number of GAA expansion (typical is 7-34) is correlated with disease severity. Diagnosis needs to be confirmed with Genetic testing with triplet repeat expansions of the first axon of the Frataxin gene. Decreased production of "Frataxin" causes impairment of enzymatic antioxidants, which in turn causes the impaired function of the brain, pancreas, and heart [3,4].

The most common age of diagnosis of Friedrich's ataxia is before 25 years. However, late onset cases (15%) might be diagnosed between 26-39 years. Also, cases of very late onset Friedrich's ataxia (1-2% only) could be presented after 40 years [1,3]. The most common manifestation for Friedrich's ataxia is neurological dysfunction and cardiomyopathy. Friedrich's ataxia has some universal features, such as progressive ataxia of all four limbs, loss of deep tendon reflex, motor weakness, and cerebellar dysarthria. Sensory loss of a distal limb has been shown to affect 73 to 92 percent of patients [3]. It involves proprioception and vibration sense, reflecting the spinal cord's posterior column, dorsal root, and peripheral sensory axonal neuropathy. Other associated features include hearing loss (8-22%), lack of visual acuity, and optic atrophy (13-27%) [5]. Patients with fewer repetitions will present late and have less chance of cardiomyopathy [5]. Kyphoscoliosis could be the first sign before neurological symptoms. Motor neuropathy can present with pes cavus, hammer toes (54-72%), and atrophy of the intrinsic muscle of the hand. However, patients' cognition is usually preserved [6].

## 2. CASE HISTORY

We examine an 83-year-old male with bilateral upper limb tremor, and spasticity gradually worsened in recent years. He and his sister were diagnosed with Friedrich's ataxia 23 years ago. At that time, the patient presented with ataxia and motor weakness, which gradually worsened throughout the years. As a result of further progression of his neurological function, he needs assistance in his daily activities (bathing,

dressing, cooking, feeding, and transferring from chair to bed) for the past 15 years. In addition, he has bilateral foot drop with occasional neuropathic pain, which he tried to overcome with physical therapy and occasional pain medication. During the past two years, he developed a bilateral upper limb resting tremor-mild in intensity initially, which turned to moderate intensity recently. Considering the nature of tremor and no other possible causes, the neurologist started Levodopa and Carbidopa (low dose) for trial.

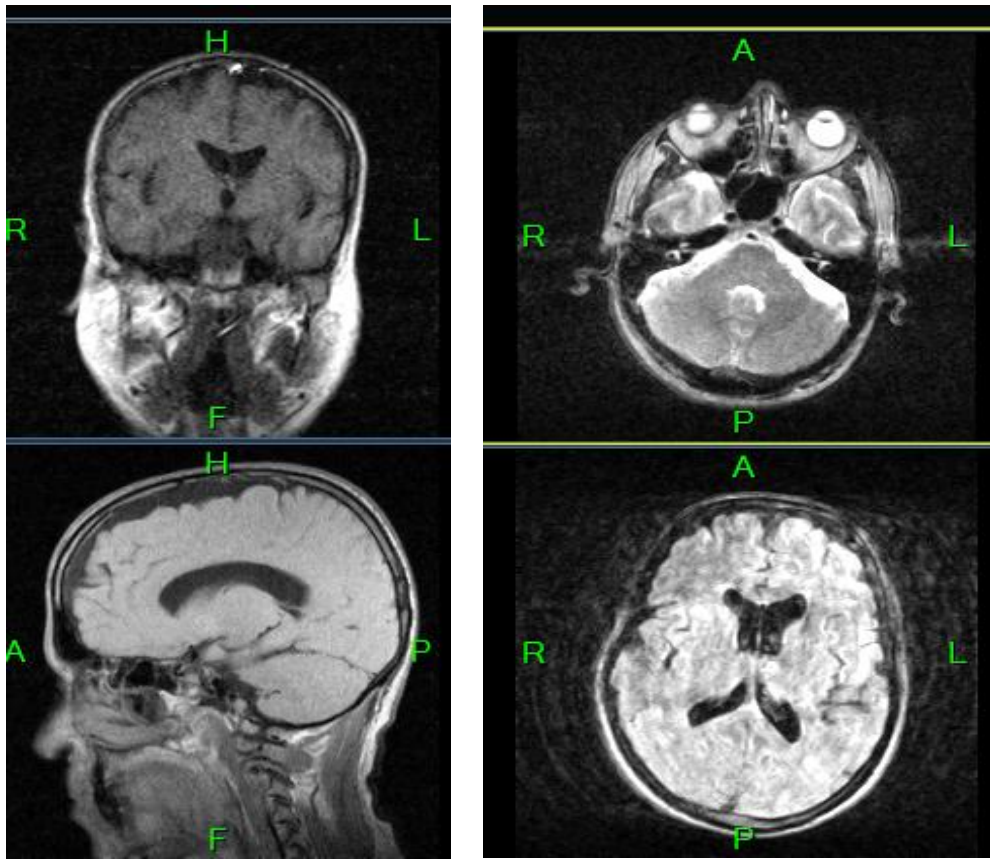
In his follow-up two years ago, he mentioned a mild improvement of tremor and ataxia with medications. Therefore, the neurologist planned a further follow-up in 6 months, when the patient presented his tremor as worsening and needed a further increase in his medication dosage. However, one year later, there was no change of tremor, ataxia, and motor weakness after his subsequent follow-up. Therefore, the neurologist advised to decrease the dose to the previous level and follow up in 2 months. Since then, his condition was stable with this symptomatic treatment with regular physical therapy and other medications for his comorbidities.

Other comorbidities for the patient include hypertension for 20 years and BPH (Benign Prostatic Hyperplasia). Diabetes, common in Friedrich ataxia, is not present in our patient. There is no history of fall or trauma. He is a non-smoker who has no history of alcohol use and who lives in an assisted facility.

The patient's cognition and speech are found normal. His spinal examination is normal, there is no scoliosis. He has never experienced any hearing and visual impairment or bowel, bladder changes. While reviewing his other systems, we haven't observed any abnormalities.

On a recent examination, his vitals were stable. On neurological examinations, muscle power came out 3/5, and the patient retained reflex bilaterally. There was no visible muscle atrophy, loss of sensation, vibration, or position sense and cranial nerve function remained intact. No abnormalities in the musculoskeletal system were observed. Gait was not evaluated due to restriction of movement.

Diagnosis of Friedrich's ataxia was made based on patient history, physical examination, and family history. However, a genetic analysis report has not been available.



**Fig. 1. MRI without enhancement: No acute changes, no hemorrhage, no mass effect**

The patient's MRI without enhancement findings in 2021 included no acute hemorrhage, no parenchymal mass effect, and patent basal cisterns. In addition, the carotid color doppler study found no significant differences, while an EEG is being considered for the near future. Besides, complete blood count, basic metabolic panel, fasting blood sugar, TSH, and urine analysis were normal.

The patient is educated about the progressive nature of the disease and regular follow-up to control complications. In addition, the patient receives Vitamin B12 injections, Levodopa-Carbidopa, Nitrate, Amlodipine, Finasteride, Pramipexole, Pravastatin, Lipoic acid, Apixaban, and Quinapril. The patient was previously treated with Idebenone, an antioxidant to help reduce oxidative injury. Nonetheless, it was not helpful for improving the patient's condition.

The most common cause of Friedrich's ataxia is having two copies of the mutated FXN gene with expanded GAA trinucleotide repeat. Therefore, family history is a significant risk factor in the case of inherited ataxia.

The slow progressive deterioration of his daily activities could be due to his disease condition and the aging process. However, there were no changes in his cognition and spinal deformity with a dopamine agonist treatment.

### 3. DISCUSSION

Friedrich's ataxia usually presents with an MRI finding of atrophy of the spinal cord and medulla [7]. Nerve conduction study would show reduced or absent sensory nerve action potential [8]. In neuropathology findings, there is thinning of dorsal nerve roots and degeneration of the posterior column of the spinal cord [9].

Late-onset Ataxia telangiectasia is often misdiagnosed as Friedrich's ataxia since Ataxia telangiectasia is present with progressive cerebellar ataxia, abnormal eye movement, and ATM (Ataxia Telangiectasia) gene mutation with increased AFP (alpha-fetoprotein) [10]. Similarly, Charcot-Marie-Tooth disease (Roussy-Levy variant) presents with ataxia and areflexia. However, Charcot-Marie-Tooth disease is different from Friedrich's ataxia with peripheral

demyelinating neuropathy rather than axonal neuropathy [10].

Multiple System atrophy with predominant Parkinsonism type is characterized by akinesia/bradykinesia, rigidity, postural instability, irregular postural jerky movement, and action tremor. Nevertheless, the rapid progression nature of Multiple system atrophy regardless of dopaminergic treatment is different from Friedrich's ataxia.

Our management plan includes an occupational and physical therapy program to improve balance and motor control. In addition, the patient would need annual cardiac and swallowing evaluation, eye examination, and scoliosis screening. Other essential follow up comprises diabetes test, urodynamic study, and sleep study [10]. Other treatment options for Friedrich's ataxia include virus vector gene therapy, a promising area for future research. Unfortunately, this option was not available for practice at the time of this writing due to immunotoxicity and phenotoxicity [11].

#### 4. CONCLUSIONS

We have a case presented with tremor-predominant Friedrich's ataxia, with a family history of a similar condition. However, comorbidities such as Parkinsonism can modify disease progression, and treatment of Parkinsonism is improving his quality of life. To the best of our knowledge, there are a few cases of Parkinsonism with Friedrich's ataxia, and the prognosis is not improved after treating with Levodopa and Carbidopa. However, in our circumstances, low to moderate doses with occasional dose intervals are helping the patient to achieve maximum quality of life. The role of this medication has not yet been established and would require further investigations.

Late-onset disease is usually slow in progression. The patient is doing well with tremor and ataxia symptomatic management, as he is prescribed Levodopa and Carbidopa with regular follow-up.

#### CONSENT AND ETHICAL APPROVAL

As per international standard or university standard guideline patients consent and ethical approval has been collected and preserved by the authors.

#### COMPETING INTERESTS

Authors have declared that no competing interests exist.

#### REFERENCES

1. Cossée M, Schmitt M, Campuzano V, Reutenauer L, Moutou C, Mandel JL: Evolution of Friedreich's ataxia trinucleotide repeat expansion: Founder effect and permutations. *Proc Natl Acad Sci USA*. 1997;94:7452-7. DOI:ORG/101073/PNAS.94.14.7452
2. Cossée M, Schmitt M, Campuzano V, Reutenauer L, Moutou C, Mandel JL: Friedreich's ataxia: an autosomal recessive disease caused by an intronic GAA triplet repeat expansion. *Science*. 1996;271:1423. DOI:10.1126/science.271.5254.1423
3. Koutnikova H, Campuzano V, Foury F, et al.: Studies of the human, mouse, and yeast homologs indicate a mitochondrial function for frataxin. *Nat Genet*. 1997; 16:345. DOI.ORG/10.1038/NG0897-345
4. Koeppen AH: Friedreich's ataxia: pathology, pathogenesis, and molecular genetics. *J Neurol Sci*. 2011;303:1. DOI.ORG/10.1016/J.JNS.2011.01.010
5. Dürr A, Cossee M, Agid Y, et al.: Clinical and genetic abnormalities in patients with Friedreich's ataxia. *N Engl J Med*. 1996; 335:1169. DOI:10.1056/NEJM199610173351601
6. Delatycki MB, Corben LA: Clinical features of Friedreich ataxia. *J Child Neurol*. 2012; 27:1133. DOI.ORG/10.1177/0883073812448230
7. Wüllner U, Klockgether T, Petersen D, et al.: Magnetic resonance imaging in hereditary and idiopathic ataxia. *Neurology*. 1993;43:318. DOI.ORG/10.1212/WNL.43.2.318
8. Schulz JB, Boesch S, Bürk K, et al.: Diagnosis and treatment of Friedreich ataxia: a European perspective. *Nat Rev Neurol*. 2009;5:222. DOI.ORG/10.1038/NRNEUROL.2009.26
9. Koeppen AH, Mazurkiewicz JE: Friedreich ataxia: neuropathology. *J Neuropathol Exp Neurol*. 2013;72:78. DOI.ORG/10.1097/Nen.0b013e31827e5762
10. Opal P, Zoghbi HY. Friedreich's ataxia. In Patterson MC, Firth HV, Eichler A; 2021.

- Available:<https://www.uptodate.com/contents/friedreich-ataxia>.  
11. Ocana-Santero G, Díaz-Nido J, Herranz-Martín S. Future Prospects of Gene Therapy for Friedreich's Ataxia. *Int J Mol Sci.* 2021;22(4):1815.  
2021 Feb 11.  
DOI:10.3390/IJMS22041815.

---

© 2021 Gupta and Chowdhury; This is an Open Access article distributed under the terms of the Creative Commons Attribution License (<http://creativecommons.org/licenses/by/4.0>), which permits unrestricted use, distribution, and reproduction in any medium, provided the original work is properly cited.

*Peer-review history:*  
The peer review history for this paper can be accessed here:  
<https://www.sdiarticle4.com/review-history/72138>